

Diagnostic and Therapeutic Pitfalls Associated with Primaquine-Tolerant *Plasmodium vivax*

Jeanne M. Spudick,¹ Lynne S. Garcia,² David M. Graham,¹
and David A. Haake^{1,3*}

Veterans Affairs Greater Los Angeles Healthcare System¹ and Department of Medicine,
David Geffen School of Medicine at UCLA,³ Los Angeles, and LSG & Associates,
Santa Monica,² California

Received 19 June 2004/Returned for modification 6 August 2004/Accepted 30 September 2004

We describe a U.S. Army Ranger returning from duty in Afghanistan and Iraq with life-threatening infection due to *Plasmodium vivax*. Morphological variants were observed in blood films prepared using samples collected by venipuncture. The patient's multiple relapses indicate infection with primaquine-tolerant *P. vivax*. Strategies for relapse prevention using primaquine are reviewed.

CASE REPORT

A 21-year-old male U.S. Army Ranger was deployed to Afghanistan and Iraq from March through May 2003. He received weekly mefloquine prophylaxis in Afghanistan, daily doxycycline in Iraq, and primaquine terminal prophylaxis (15 mg per day for 14 days) after returning to the United States. He began to experience malaise and intermittent fevers, and on June 26 he presented with a fever to 104°F, hypotension, tachycardia, hypoxemia, anemia, and thrombocytopenia. His blood smear revealed *Plasmodium vivax*, and treatment was initiated with chloroquine and primaquine. His condition rapidly deteriorated, including intubation for ventilatory support. Although *Plasmodium falciparum* parasitemia was never documented, the possibility of dual infection with *P. vivax* and *P. falciparum* was considered and treatment for *P. falciparum* was added (Fig. 1). The patient's hospital course was complicated by acute respiratory distress syndrome (ARDS) and prolonged mechanical ventilation with barotrauma and bilateral pneumothoraces. The patient's pulmonary function eventually improved, and he was discharged from the hospital on 3 September. On 20 September, he developed pleuritic chest pain and was found to have a large left-side pneumothorax requiring surgical management. Postoperatively, he developed fever to 103°F, and blood smears revealed *P. vivax* (0.3% parasitemia). Treatment with chloroquine and 14 days of primaquine while in the hospital resulted in negative blood smears on 23 October and 14 November. The patient was well until 16 December, when a third *P. vivax* relapse occurred (0.8% parasitemia). Because of the recurrent relapses, *P. vivax* infection was confirmed by PCR at the Centers for Disease Control and Prevention in Atlanta, Ga. PCR assays for *P. falciparum*, *Plasmodium ovale*, and *Plasmodium malariae* were negative. The patient was again treated with chloroquine and primaquine and remained symptom free 4 months later.

P. vivax causes >50% of malaria cases in the Middle East, Asia, the Western Pacific, and Central and South America, causing an estimated 70 to 80 million cases annually (13). In addition, *P. vivax* prevalence increases in war zones due to social disruption and urban damage (18). Though not as pathogenic as *P. falciparum*, *P. vivax* can produce serious and potentially life-threatening infections. Most chemoprophylaxis regimens are focused on prevention of *P. falciparum* infection and usually do not include primaquine, which is the primary drug used for elimination of latent *P. vivax* infection in the liver. Many health professionals are not familiar with the use of primaquine for primary chemoprophylaxis and relapse prevention in *P. vivax* infection. Infectious-disease specialists should also be aware of how the morphology of *P. vivax* parasites is affected by current blood collection methods. Given the large numbers of military and civilian personnel deployed to the Middle East, it is anticipated that malaria due to *P. vivax* will be seen with increasing frequency.

Clinical manifestations of *P. vivax* infection. Although *P. vivax* infection has been referred to as “benign” malaria, symptoms are frequently severe and debilitating (13). Although patients who are immunologically naïve tend to develop symptoms sooner than those with prior exposure to *P. vivax*, severe symptoms can occur in anyone (13). Typically, *P. vivax* infection produces high fever, chills, nausea, vomiting, and malaise. Paroxysms of fever are associated with high levels of tumor necrosis factor (11) induced by parasite glycosylphosphatidylinositol released during schizont rupture (20). Unlike *P. falciparum*, *P. vivax* does not cause microvascular sequestration of parasitized red cells. However, as illustrated by our case, *P. vivax* infection can be life threatening. ARDS and other pulmonary complications are well documented in *P. vivax* infection (2, 4, 7, 10, 14, 16, 17, 26, 27). Coinfection with *P. falciparum* should be considered in any patient with severe symptoms associated with *P. vivax* infection. Because of the severity of his initial presentation, our patient was initially treated for both *P. falciparum* and *P. vivax* infection, even though only *P. vivax* parasites were found on blood films. During a later relapse, *P. falciparum* infection was ruled out by PCR. The risk of ARDS may not be correlated with the level of parasitemia (26). Pulmonary dysfunction in *P. vivax* infec-

* Corresponding author. Mailing address: Division of Infectious Diseases, 111F, VA Greater Los Angeles Healthcare System, Los Angeles, CA 90073. Phone: (310) 268-3814. Fax: (310) 268-4928. E-mail: dhaake@ucla.edu.

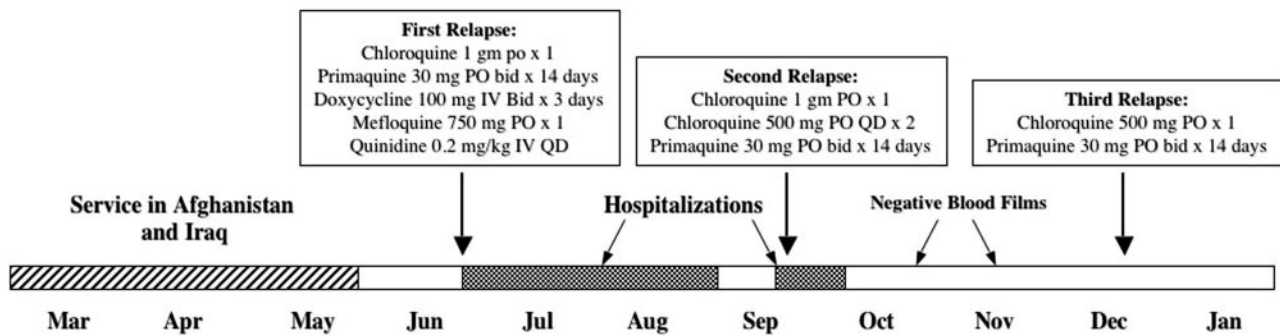


FIG. 1. Time course of patient's *P. vivax* exposure, relapses, and treatment. See the text for details.

tion is probably more common than is generally recognized (2). Lung injury is thought to be mediated by inflammatory mechanisms, as demonstrated by studies showing increased pulmonary phagocytic activity in *P. vivax* patients (2). Interestingly, in a number of cases, the pulmonary manifestations became evident after antimalarial therapy was initiated (4, 7, 14, 26), perhaps suggesting that lysis of organisms provokes the inflammatory reaction that leads to lung injury. A similar phenomenon is seen in pneumonia due to *Pneumocystis jiroveci*.

Pitfalls in diagnosis of *P. vivax* infection. Direct microscopic examination of parasites in stained thin and thick blood films remains the standard diagnostic approach. Thick films allow a larger amount of blood to be examined, which increases the possibility of detecting the light parasitemia (usually <2%) seen with *P. vivax* infection, since *P. vivax* infects only immature red blood cells (12). Species identification within the genus *Plasmodium* requires examination of the thin film, in which the morphological characteristics of the parasites within the red blood cells can more easily be seen. Both types of blood films should be carefully examined prior to reporting "no parasites seen." It is also important to remember that one set of negative blood films does not rule out malaria, especially in patients with a low level of parasitemia (8).

Optimal morphology of malaria parasites is observed in finger stick blood films prepared at the bedside. However, finger stick blood collection has for the most part been replaced with venipuncture collection using anticoagulants. For this reason, morphological changes in the parasite resulting from venipuncture must be taken into consideration when reviewing the blood films. It is important to fill the tube with blood; this ensures a correct ratio of blood to anticoagulant. If this ratio is incorrect, parasite morphological distortion may occur. If the smears are prepared from anticoagulated blood that is >1 h old, the morphology of the parasites may not be typical and the film may wash off the slide during the staining procedure. After 6 h, the parasitemia will be less than that seen immediately after the blood is drawn. Also, the longer the blood stands in the tube prior to blood film preparation, the more morphological distortion of the parasites occurs. The overall organism morphology may begin to look quite different from slides prepared with finger stick blood, and identification errors can easily occur. Diagnostic characteristics that are commonly described may not be seen at all. For example, in cases of *P. vivax* malaria, the presence of stippling (Schüffner's dots) may not be visible (Fig. 2A to C). If the cap of the lavender-top EDTA tube is removed and the blood cools, conditions in the

specimen will mimic those found in the mosquito vector. Consequently, if mature male gametocytes are present (Fig. 2E), these stages tend to undergo exflagellation and may mimic *Borrelia* organisms (Fig. 2F). If fertilization of the female gametocytes (Fig. 2D) occurs, the ookinetes of *Plasmodium* species other than *P. falciparum* may develop as if they were in the mosquito and may mimic the crescent-shaped gametocytes of *P. falciparum* (24). In order to avoid these potential problems, the immediate preparation of stained thick and thin blood films for manual examination is recommended. Each request for blood film examination for blood parasites should be considered a stat request.

***P. vivax* chemoprophylaxis.** Primary prophylaxis for malaria is usually focused on the intraerythrocytic stage of malaria. Most antimalarial drugs have no activity against the initial stages of *P. vivax* infection, including the sporozoites inoculated by mosquitoes and the hypnozoites infecting the liver. Unlike *P. falciparum*, *P. vivax* is able to establish a latent infection that typically results in relapse after return from the malarious area when primary prophylaxis is discontinued. Although malarone (atovaquone plus proguanil) probably has some activity against the hepatic phase of *P. vivax* infection, primaquine is the primary drug used for relapse prevention. Primaquine terminal prophylaxis, taken for 2 weeks after departure from the malarious area, is not frequently used and is recommended only for persons with prolonged exposure in areas where *P. vivax* is endemic, such as missionaries and Peace Corps volunteers (<http://www.cdc.gov/travel/diseases/malaria/>). Because of gastrointestinal intolerance, many malaria specialists and patients prefer to wait and see whether malaria develops before instituting primaquine. A recent study of U.S. travelers found that 811 of 987 (82%) cases of late-onset (>2 months after return) imported malaria were due to *P. vivax*, and 62% of these patients reported use of a non-primaquine-containing antimalarial regimen (21). *P. vivax* is the predominant form of malaria in Afghanistan and Iraq. Between 1981 and 1989, a total of 7,683 cases of malaria were acquired in Afghanistan by troops from the former USSR, many with late onset of malaria consistent with *P. vivax* infection (23). During the present deployment, troops on patrol at night taking advantage of the use of night vision devices are particularly at risk of exposure to the nocturnally active *Anopheles* mosquito (18).

Relapse prevention. Treatment of *P. vivax* infection involves administration of chloroquine followed by primaquine after glucose-6-phosphate dehydrogenase (G6PD) deficiency has been ruled out. Chloroquine is given to treat the asexual blood

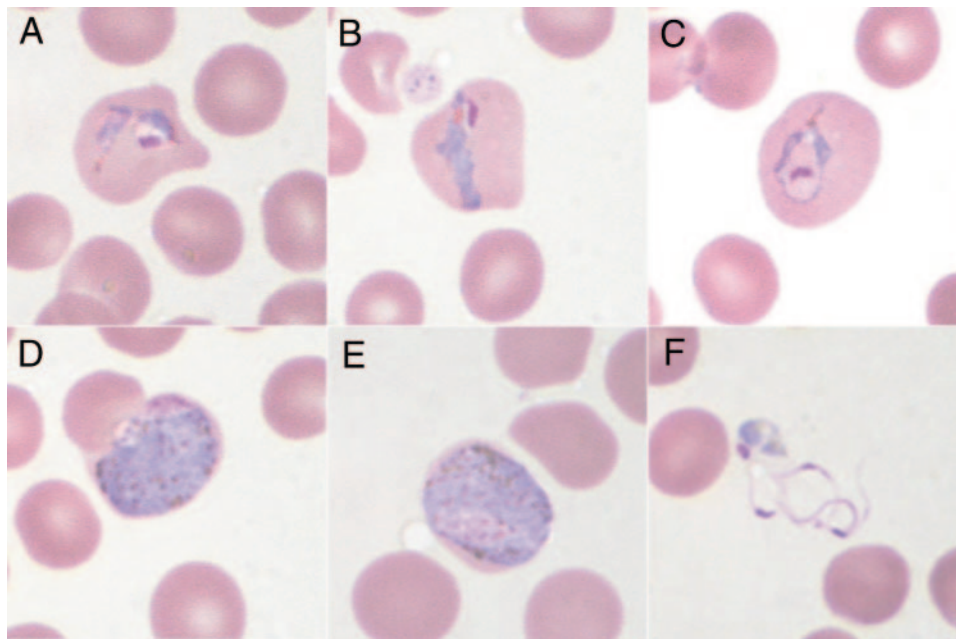


FIG. 2. *P. vivax* trophozoites (A, B, C) and gametocytes (D, E, F). The images of *P. vivax* trophozoites demonstrate (A) the absence of stippling (Schüffner's dots), (B) a "band" form (mimic of *P. malariae* but showing an enlarged cell), and (C) an enlarged erythrocyte without stippling present (lack of stippling was due to delay in blood film preparation from anticoagulated blood). The images of *P. vivax* gametocytes include (D) a female macrogametocyte (note the compact pink nuclear chromatin), (E) a male macrogametocyte (note the more diffuse pink nuclear chromatin), and (F) male microgametes with a residual body (produced from the exflagellation of the male microgametocyte due to delay in blood film preparation from anticoagulated blood).

stages of the parasite, and primaquine is given to prevent relapse by eliminating hypnozoites latent in the liver. This drug combination strategy is referred to as a radical cure, defined as the complete eradication of parasites from the body. Since chloroquine resistance in *P. vivax* has now been described in several areas (28), follow-up blood smears should be obtained 28 days after chloroquine therapy to ensure that recrudescence of blood-stage infection has not occurred. Our patient's negative blood smears 23 and 45 days after treatment of infection in September and the timing of the reappearance of infection in December indicate relapse of latent liver infection. Relapse after appropriate therapy strongly indicates primaquine tolerance of the *P. vivax* strain causing infection in our patient.

A recent paper by Baird and Rieckmann reviews ways that *P. vivax* relapse prevention using primaquine can be improved (3). For example, preclinical studies of nonhuman primates and early clinical studies showed that the total dose of primaquine rather than the dosing schedule determined the efficacy of treatment (1, 6, 19). For many years, the standard dose of primaquine was 15 mg per day for 14 days (total dose, 210 mg) because studies performed >40 years ago showed that this was effective in preventing relapse for all *P. vivax* strains except the Chesson strain in New Guinea. Since that time, primaquine tolerance appears to have emerged in *P. vivax* strains found in many areas. Primaquine is only 80% effective in Southeast Asia (3), and in U.S. Army troops deployed to Somalia in 1993, the 210-mg regimen had a relapse prevention failure rate of 43% (25). For this reason, the Centers for Disease Control and Prevention have recently increased the recommended dose of primaquine from 15 to 30 mg per day for 14 days (http://www.cdc.gov/malaria/diagnosis_treatment/tx_clinicians.htm). Be-

cause higher primaquine doses are more effective than lower doses, these *P. vivax* strains are thought to be primaquine tolerant rather than truly resistant. However, because the organism cannot be propagated in vitro, inoculation in nonhuman primates is required to study the responsiveness of *P. vivax* strains to primaquine (15).

Several studies have indicated the importance of adjusting the total primaquine dose for the weight of the patient. A retrospective review of 15 Israeli travelers who returned from Ethiopia noted eight relapses in five of the patients despite a total dose of 210 mg of primaquine (15 mg per day for 14 days). Retrospective calculation of the primaquine dose per kilogram of body weight for the 23 treatment courses noted a lower total dose per kilogram in heavier patients. The mean calculated dose ($\pm 95\%$ confidence interval) in the eight patients who failed treatment was 2.5 ± 0.3 mg/kg compared with 4.4 ± 0.5 mg/kg in the 15 successfully treated patients. They concluded that weight-adjusted dosing may prevent inadvertent subtherapeutic drug therapy and apparent primaquine failure (22). A study done in Brazil evaluated the cure rate in patients receiving 210 mg of primaquine for treatment of *P. vivax* infection and assessed the risk factors for failure. The dose per kilogram of body weight was calculated, and the association of this variable with relapses was assessed. Among the 50 patients, seven relapses were noted. The mean total dose of primaquine (mean \pm standard deviation) was lower for the patients who relapsed (2.76 ± 0.52 mg/kg) than for the overall population of patients (3.26 ± 0.68 mg/kg) or for those who did not relapse (3.35 ± 0.67 mg/kg). The total primaquine dose per kilogram of body weight was the only variable associated with relapse (9).

Primaquine toxicity. Primaquine should never be given without testing for G6PD deficiency. Primaquine-induced acute intravascular hemolysis in patients with the Mediterranean B variant of G6PD deficiency can be life threatening. Many variants of this genetic disorder exist, and the level of G6PD activity is not necessarily correlated with the severity of hemolysis. In patients without G6PD deficiency, the primary side effects of primaquine involve gastrointestinal toxicity. Abdominal distress occurs in 5, 10, 35, and 100% of fasting volunteers given a single dose of 15, 30, 45, or 90 mg of primaquine, respectively (5). However, the same study reported complete relief of symptoms in patients given primaquine with food. Dosing of primaquine with a snack or meal is recommended to decrease gastrointestinal side effects.

Since primaquine remains the only drug available with hypnozoitocidal activity against *P. vivax*, physicians need to be familiar with how to effectively use primaquine for chemoprophylaxis and relapse prevention. The spread of primaquine-resistant *P. vivax* beyond Southeast Asia points to the need for newer antimalarial medications. A promising new primaquine analog named tafenoquine is currently in phase III clinical trials (3). Tafenoquine appears to have activity against *P. vivax*, and its improved pharmacokinetics (mean half-life, 361 h compared to primaquine's half-life of 6 h) would also address problems related to compliance with primaquine therapy. Given the shortcomings of current malaria prophylaxis regimens, health care providers need to have a heightened awareness and suspicion of malaria when evaluating acutely ill travelers from malarious regions, regardless of their chemoprophylaxis history. Clinicians should also be aware of how current methods for preparing blood smears affect the morphology of *P. vivax* parasites. As this report was being prepared, a second U.S. Army Ranger stationed in Afghanistan and Iraq presented to our facility with a case of *P. vivax* malaria. We anticipate that as military and civilian personnel continue to be deployed to malarious regions of the world, a greater number of patients with *P. vivax* infection will be cared for by physicians and microbiologists. It is essential that health care providers, both at the bedside and in the clinical microbiology laboratory, be familiar with the pitfalls in the diagnosis and treatment of malaria due to *P. vivax*.

We thank the Clinical Microbiology Laboratory at the VA Greater Los Angeles Healthcare System for their expert technical assistance in correctly identifying the *P. vivax* parasites and for recognition of the unusual morphological variants resulting from the length of time the blood sample had been stored in the tube prior to preparation of blood smears. We also thank the Centers for Disease Control and Prevention in Atlanta for advice on treatment and for PCR confirmation of *P. vivax* infection.

There was no financial support for this work.

None of the authors had potential conflicts of interest.

REFERENCES

- Alving, A. S., C. F. Johnson, A. R. Tarlov, G. J. Brewer, R. W. Kellermeier, and P. E. Carson. 1960. Mitigation of the haemolytic effect of primaquine and enhancement of its action against exoerythrocytic forms of the Chesson strain of *Plasmodium vivax* by intermittent regimens of drug administration: a preliminary report. *Bull. W. H. O.* **22**:621–631.
- Anstey, N. M., S. P. Jacups, T. Cain, T. Pearson, P. J. Ziesing, D. A. Fisher, B. J. Currie, P. J. Marks, and G. P. Maguire. 2002. Pulmonary manifestations of uncomplicated falciparum and vivax malaria: cough, small airways obstruction, impaired gas transfer, and increased pulmonary phagocytic activity. *J. Infect. Dis.* **185**:1326–1334.
- Baird, J. K., and K. H. Rieckmann. 2003. Can primaquine therapy for vivax malaria be improved? *Trends Parasitol.* **19**:115–120.
- Carlini, M. E., A. C. White, Jr., and R. L. Atmar. 1999. Vivax malaria complicated by adult respiratory distress syndrome. *Clin. Infect. Dis.* **28**:1182–1183.
- Clayman, C. B., J. Arnold, R. S. Hockwald, E. H. Yount, Jr., J. H. Edgcomb, and A. S. Alving. 1952. Toxicity of primaquine in Caucasians. *JAMA* **149**:1563–1568.
- Clyde, D. F., and V. C. McCarthy. 1977. Radical cure of Chesson strain vivax malaria in man by 7, not 14, days of treatment with primaquine. *Am. J. Trop. Med. Hyg.* **26**:562–563.
- Curlin, M. E., L. M. Barat, D. K. Walsh, and D. L. Granger. 1999. Noncardiogenic pulmonary edema during vivax malaria. *Clin. Infect. Dis.* **28**:1166–1167.
- Dourado, H. V., N. P. Abdon, and S. J. Martins. 1994. Falciparum malaria. Epidemiology in Latin America, biologic and clinical considerations, treatment, and prophylaxis. *Infect. Dis. Clin. N. Am.* **8**:207–223.
- Duarte, E. C., L. W. Pang, L. C. Ribeiro, and C. J. Fontes. 2001. Association of subtherapeutic dosages of a standard drug regimen with failures in preventing relapses of vivax malaria. *Am. J. Trop. Med. Hyg.* **65**:471–476.
- Islam, N., and K. Qamruddin. 1995. Unusual complications in benign tertian malaria. *Trop. Geogr. Med.* **47**:141–143.
- Karunaweera, N. D., G. E. Grau, P. Gamage, R. Carter, and K. N. Mendis. 1992. Dynamics of fever and serum levels of tumor necrosis factor are closely associated during clinical paroxysms in *Plasmodium vivax* malaria. *Proc. Natl. Acad. Sci. USA* **89**:3200–3203.
- Kitchen, S. K. 1938. The infection of reticulocytes by *Plasmodium vivax*. *Am. J. Trop. Med.* **18**:347–353.
- Mendis, K., B. J. Sina, P. Marchesini, and R. Carter. 2001. The neglected burden of *Plasmodium vivax* malaria. *Am. J. Trop. Med. Hyg.* **64**:97–106.
- Munteis, E., L. Mellibovsky, M. A. Marquez, S. Minguez, E. Vazquez, and A. Diez. 1997. Pulmonary involvement in a case of *Plasmodium vivax* malaria. *Chest* **111**:834–835.
- Nayar, J. K., R. H. Baker, J. W. Knight, J. S. Sullivan, C. L. Morris, B. B. Richardson, G. G. Galland, and W. E. Collins. 1997. Studies on a primaquine-tolerant strain of *Plasmodium vivax* from Brazil in Aotus and Saimiri monkeys. *J. Parasitol.* **83**:739–745.
- Perren, A., F. Beretta, and P. Schubarth. 1998. ARDS in *Plasmodium vivax* malaria. *Schweiz. Med. Wochenschr.* **128**:1020–1023.
- Pukrittayakamee, S., A. Chantira, S. Vanijanonta, and N. J. White. 1998. Pulmonary oedema in vivax malaria. *Trans. R. Soc. Trop. Med. Hyg.* **92**:421–422.
- Schlagenhauf, P. 2003. Malaria in Iraq—the pitfalls of *Plasmodium vivax* prophylaxis. *Lancet Infect. Dis.* **3**:460.
- Schmidt, L. H., R. Fradkin, D. Vaughan, and J. Rasco. 1977. Radical cure of infections with *Plasmodium cynomolgi*: a function of total 8-aminoquinoline dose. *Am. J. Trop. Med. Hyg.* **26**:1116–1128.
- Schofield, L., and F. Hackett. 1993. Signal transduction in host cells by a glycosylphosphatidylinositol toxin of malaria parasites. *J. Exp. Med.* **177**:145–153.
- Schwartz, E., M. Parise, P. Kozarsky, and M. Cetron. 2003. Delayed onset of malaria—implications for chemoprophylaxis in travelers. *N. Engl. J. Med.* **349**:1510–1516.
- Schwartz, E., G. Regev-Yochay, and D. Kurnik. 2000. A consideration of primaquine dose adjustment for radical cure of *Plasmodium vivax* malaria. *Am. J. Trop. Med. Hyg.* **62**:393–395.
- Sergiev, V. P., A. M. Baranova, V. S. Orlov, L. G. Mihajlov, R. L. Kouznetsov, N. I. Neujmin, L. P. Arsenieva, M. A. Shahova, L. A. Glagoleva, and M. M. Osipova. 1993. Importation of malaria into the USSR from Afghanistan, 1981–89. *Bull. W. H. O.* **71**:385–388.
- Sinden, R. E., R. H. Hartley, and L. Winger. 1985. The development of *Plasmodium* ookinetes in vitro: an ultrastructural study including a description of meiotic division. *Parasitology* **91**:227–244.
- Smoak, B. L., R. F. DeFraithe, A. J. Magill, K. C. Kain, and B. T. Welde. 1997. *Plasmodium vivax* infections in U.S. Army troops: failure of primaquine to prevent relapse in studies from Somalia. *Am. J. Trop. Med. Hyg.* **56**:231–234.
- Tanios, M. A., L. Kogelman, B. McGovern, and P. M. Hassoun. 2001. Acute respiratory distress syndrome complicating *Plasmodium vivax* malaria. *Crit. Care Med.* **29**:665–667.
- Torres, J. R., H. Perez, M. M. Postigo, and J. R. Silva. 1997. Acute noncardiogenic lung injury in benign tertian malaria. *Lancet* **350**:31–32.
- Wellem, T. E., and C. V. Plowe. 2001. Chloroquine-resistant malaria. *J. Infect. Dis.* **184**:770–776.