

Demonstration of *Bartonella grahamii* DNA in Ocular Fluids of a Patient with Neuroretinitis

F. T. KERKHOFF,^{1*} A. M. C. BERGMANS,² A. VAN DER ZEE,² AND A. ROTHOVA¹

Department of Ophthalmology, F. C. Donders Institute, University Hospital, Utrecht,¹ and Laboratory of Molecular Microbiology, St. Elisabeth Hospital, Tilburg,² The Netherlands

Received 26 April 1999/Returned for modification 4 June 1999/Accepted 24 August 1999

We describe the clinical and laboratory features of a 55-year-old human immunodeficiency virus-negative female patient who presented with bilateral intraocular inflammatory disease (neuroretinitis type) and behavioral changes caused by a *Bartonella grahamii* infection. Diagnosis was based on the PCR analysis of DNA extracted from the intraocular fluids. DNA analysis of the PCR product revealed a 100% identity with the 16S rRNA gene sequence of *B. grahamii*. The patient was successfully treated with doxycycline (200 mg/day) and rifampin (600 mg/day) for 4 weeks. This is the first report that demonstrates the presence of a *Bartonella* species in the intraocular fluids of a nonimmunocompromised patient and that indicates that *B. grahamii* is pathogenic for humans.

The spectrum of diseases attributed to *Bartonella* species is still expanding; so far, four species, *B. henselae*, *B. quintana*, *B. bacilliformis*, and *B. elizabethae*, have been identified as causes of human disease (16). *B. grahamii* (formerly known as *Grahamella*) has been found in small rodents, but was, to our knowledge, never implicated in human infections (3, 11).

Ocular involvement in the course of *Bartonella* infections is being recognized with increasing frequency, with *B. henselae* being the most frequently encountered species (9, 18). In the past, ophthalmological manifestations such as Parinaud's oculoglandular syndrome, papillitis, multifocal chorioretinitis, and, mainly, neuroretinitis have been associated with cat-scratch disease (CSD), especially in children and young adults (5, 18). In addition, various reports have described intraocular inflammation associated with highly positive antibody titers against *B. henselae* in patients who lacked the systemic symptoms and signs typical of generalized CSD (12, 24).

The exact pathogenesis of ocular involvement in bartonellosis is still obscure. Although the presence of *B. henselae* DNA has been described in the retina of an AIDS patient, it is not known whether in immunocompetent patients the *Bartonella* species directly cause intraocular infection or whether ocular involvement represents a secondary (auto)immune reaction (29). We describe a patient with neuroretinitis and high levels of immunoglobulin G (IgG) against *B. henselae* in serum. PCR and sequence analysis of the PCR product identified the presence of *B. grahamii* DNA in the patient's eye.

CASE REPORT

A 55-year-old female patient was referred to our uveitis clinic for an analysis of her bilateral neuroretinitis, which was accompanied by behavioral changes.

The patient had a history of insulin-dependent diabetes mellitus from the age of 35 years and hypothyroidism, for which she was treated with insulin and levothyroxine. One year before the referral, the patient had consulted an ophthalmologist because of a progressive decrease of visual acuity in both eyes

and sudden onset of headache. Behavioral changes such as irritability and anxiety were noticed by the family members. The patient was admitted to the district hospital for further evaluation. Ophthalmological examination at that time revealed visual acuity of 20/125 in the right eye (RE) and 20/50 in the left eye (LE), inflammatory cells in the anterior chambers, posterior synechiae, vitreitis, and papillitis (Fig. 1), with macular edema and retinal vasculitis in both eyes. There were no signs of diabetic retinopathy or thyroid orbitopathy.

On general examination, no abnormalities were noticed; specifically, no signs of systemic vasculitis were present. The results of laboratory evaluations for erythrocyte and leukocyte counts and renal and liver function tests were within the normal limits, the patient was negative for HLA-B27, a test for antinuclear antibody was positive with a titer of 1:40, and the erythrocyte sedimentation rate was 66 mm per h. There was no serological evidence of infection with herpes simplex virus (HSV), varicella-zoster virus (VZV), or *Borrelia burgdorferi*. Her diabetes and thyroid status were adequately controlled.

Neurological examination disclosed no apparent abnormalities; the patient was well oriented in place and time but reacted slowly to external stimuli. A computed tomographic scan of the cerebrum showed no abnormalities. The cerebrospinal fluid (CSF) revealed a pleiocytosis without oligoclonal bands, and further microbiological analysis of the CSF disclosed no evidence of infection with HSV, VZV, enteroviruses, or *B. burgdorferi*.

A presumed diagnosis of viral encephalovirus was made, and the patient was given a course of oral prednisone (initial dose, 90 mg, together with 250 mg of acetazolamide three times daily for retinal edema). Her visual acuity and mental condition slowly improved, but her ocular inflammatory disease persisted and the patient was referred to our institution.

On presentation at our institution, her visual acuity was 20/80 in the RE and 20/30 in the LE. Anterior eye segments were normal, and old posterior synechiae were present. Posterior subcapsular opacities were noted in the lens. On dilated fundus examination, occasional cells and dense opacities were located in the vitreous humor; the optic disc and retina appeared normal except for slight macular edema and sporadic atrophic scars in the peripheral retinas of both eyes. The fluorescein angiography revealed leakage from the optic disc and

* Corresponding author. Mailing address: Department of Ophthalmology, F. C. Donders Institute, Academic Hospital Utrecht, P.O. Box 85 500, 3508 GA Utrecht, The Netherlands. Phone: (30) 2507880. Fax: (30) 250 54 17. E-mail: fkerkh@oogheel.azu.nl.

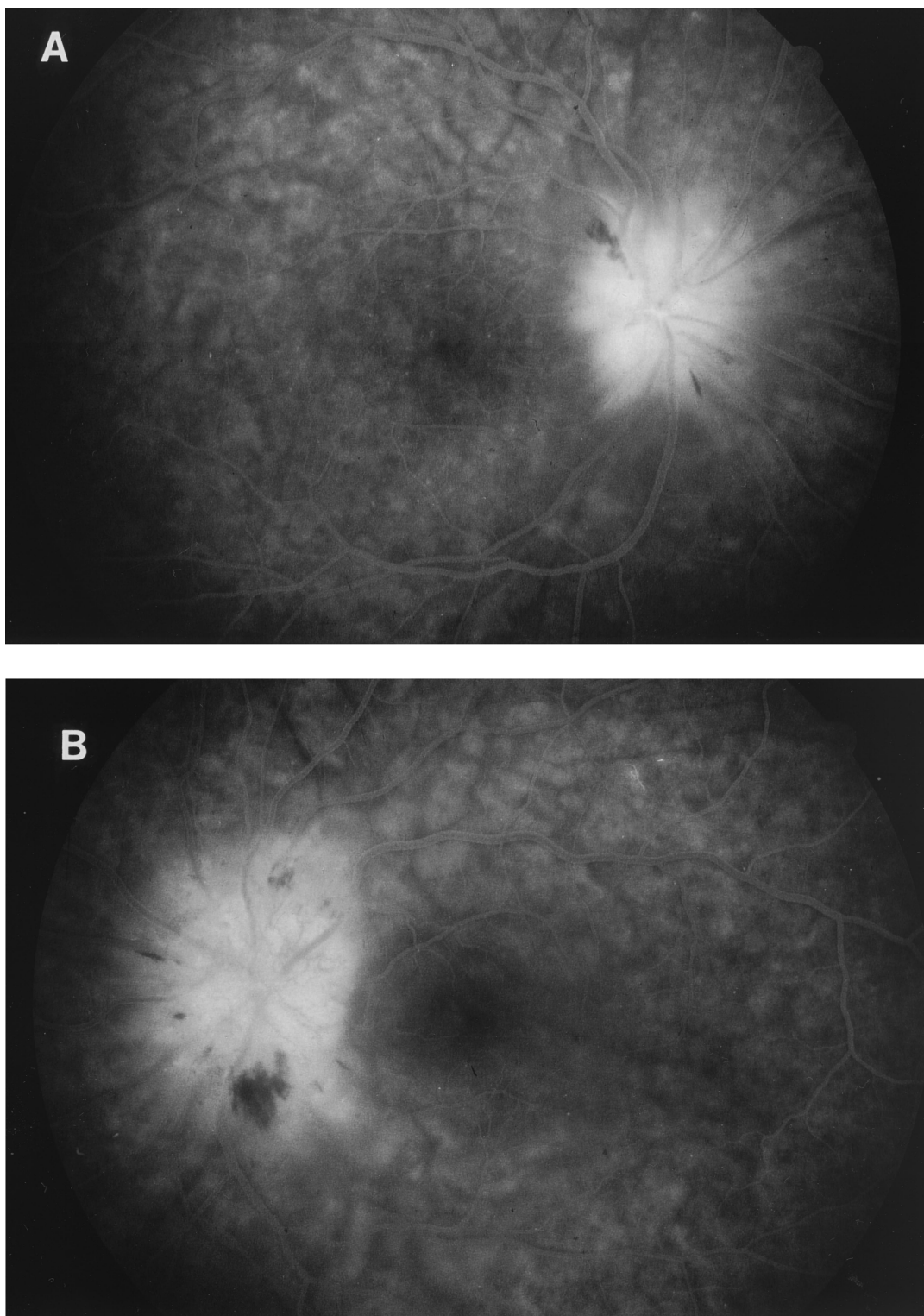


FIG. 1. Fluorescein angiogram of the right eye (A) and the left eye (B) showing a classic neuroretinitis with an extremely hyperfluorescent optic nerve with discrete peripapillary leakage of fluorescein and small peripapillary hemorrhages.

moderate cystoid macular edema. The reevaluation for uveitis included tests for erythrocyte sedimentation rate; erythrocyte and leukocyte counts; serum angiotensin-converting enzyme levels; and syphilis, *Borrelia*, and *Bartonella* serology as well as

chest radiography. Except for the *Bartonella* serological test, the results of all tests were within the normal limits. The human immunodeficiency virus (HIV) serological test was negative. The patient owned a dog and had no contact with cats.

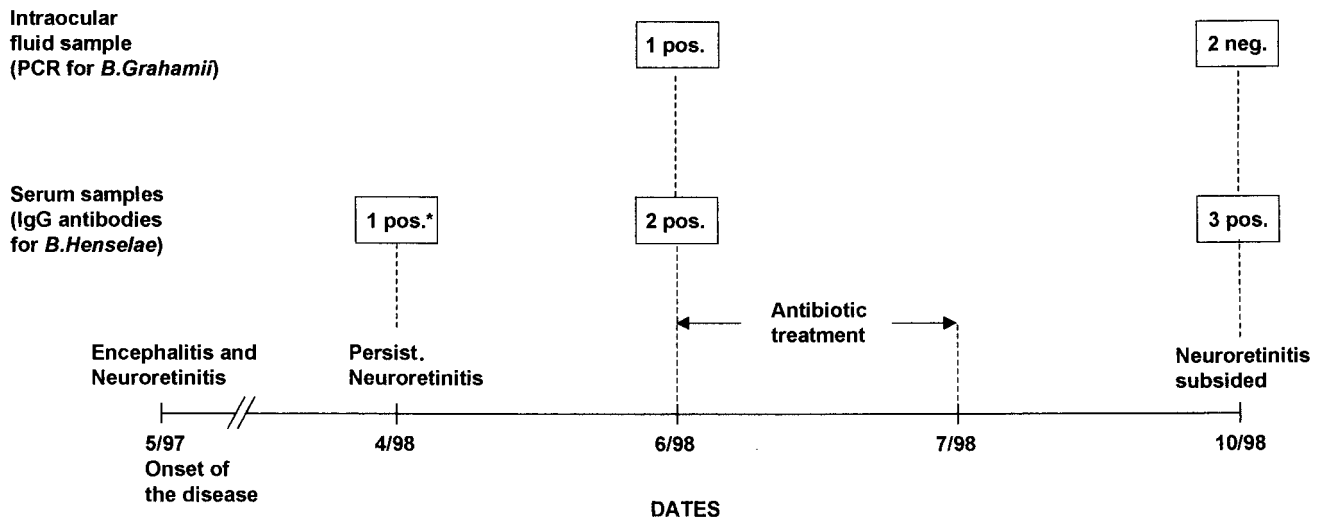


FIG. 2. Time course of clinical manifestations and detection of *B. grahamii* DNA in intraocular fluids and *B. henselae* antibodies in serum. *, determined retrospectively; pos., positive; neg., negative; Persist., persistent.

The PCR was positive for *Bartonella* and was negative for all other microorganisms evaluated.

A diagnosis of ocular bartonellosis was made, and the patient was treated with doxycycline at 200 mg/day and rifampin at 600 mg/day for 4 weeks. On ophthalmic examination 3 months after the treatment was completed, the intraocular inflammation appeared to be extinguished. Due to cataract development, however, the visual acuity had decreased (20/300 in the RE and 20/100 in the LE) and extraction of the cataract from the RE was performed. The intraocular fluid collected during the surgery was reexamined for the presence of *Bartonella* DNA. The visual acuity of the RE increased to 20/30 after cataract extraction.

MATERIALS AND METHODS

Serological analysis. Within a 6-month period in 1998, three serum samples were taken from the patient (Fig. 2). The first two serum samples were taken before antibiotic treatment; the third was taken 3 months after the treatment was completed (during the cataract surgery). The serum and CSF taken during the initial phase of the patient's disease were not stored and therefore could not be examined retrospectively. All serum samples were tested for the presence of IgG and IgM antibodies against *B. henselae* in an enzyme immunoassay (EIA) and in an indirect fluorescence assay (IFA) with *B. henselae* as the antigen, as described earlier (2). In our laboratory, the cutoff values for positive serology were 1:900 for IgG EIA, 1:250 for IgM EIA, 1:128 for IgG IFA, and 1:16 for IgM IFA (2).

DNA analysis with anterior chamber fluid. Within a 3-month period, two anterior chamber fluid samples were collected by a standard procedure (Fig. 2) (26). The first one was collected during active ocular inflammation and before the antibiotic treatment was initiated, and the second one was collected 3 months after the treatment was completed (during the cataract surgery, when there were no signs of intraocular inflammatory activity).

DNA was extracted from anterior chamber fluid with a commercially available DNA purification kit (QIAamp Blood Kit; QIAGEN AG, Basel, Switzerland). A PCR analysis was performed with the extracted DNA and with the *Bartonella*-specific primers p24E and p12B described by Relman et al. (20), but without the 5' restriction site sequences. The PCR product was hybridized by programs with a 5'-biotinylated, *B. henselae*-specific oligonucleotide probe (5'-ATTTGGTTG GGCCTCTAGGGG-3') (1). The DNA sequence of the *Bartonella* PCR product was determined with fluorescent dye dideoxide terminators in the cycling sequencing system (Applied Biosystems, Perkin-Elmer, Nieuwerkerk a.d. IJssel, The Netherlands). The DNA sequencing data were compared with the sequences in the EMBL and GenBank nucleotide sequence databases by using the FastA and BLAST comparison programs with a 5'-biotinylated, *B. henselae*-specific oligonucleotide.

RESULTS

Serological analysis. By EIA, the titers of IgG antibodies against *B. henselae* were 1:1,000 in all three serum samples, and IgM antibodies were absent. The IFA with *B. henselae* as the antigen revealed IgG titers of 1:64 and 1:32 in the serum samples before antibiotic treatment and titers of 1:32 after the treatment. By IFA, the IgM antibody titers remained less than 1:8.

Analysis of DNA from anterior chamber fluid. PCR with the *Bartonella*-specific primers and with DNA extracted from the anterior chamber fluid yielded a PCR fragment of the expected size of 300 bp. The PCR product did not hybridize with the *B. henselae*-specific oligonucleotide probe. DNA sequence analysis of the PCR product and comparison of the sequence with those present in the EMBL and GenBank nucleotide sequence databases revealed a 100% identity of DNA from the first anterior chamber fluid sample with the 16S rRNA gene sequence of *B. grahamii* (accession no. Z31349). PCRs with intraocular fluids for detection of HSV, VZV, and *Toxoplasma gondii* were also performed, and the results were negative for all microorganisms studied. With the second anterior chamber fluid sample, the PCR for *B. grahamii* was negative.

DISCUSSION

In the study described in this report we demonstrated the presence of *B. grahamii* DNA in the eye of an HIV-negative patient with neuroretinitis, which indicates the direct involvement of *Bartonella* species in neuroretinitis and further documents the possibility of *B. grahamii* infection in humans.

Uveitis, an intraocular inflammatory disease, is an important cause of severe visual impairment and blindness and causes significant morbidity in the economically active young adult population (25). Infectious processes play an important role in the pathogenesis of uveitis; specifically, herpesviruses and *T. gondii* are common causative agents in immunocompetent as well as in immunocompromised patients (8). The recognition of an infectious etiology of uveitis is important because of the consequences of the treatment; while immunosuppressive

medication is essential for the majority of patients with non-infectious uveitis, this treatment modality may induce a fulminant course of infection without specific antimicrobial treatment (21). The recently achieved ability to detect microbial DNA has led to the recognition of various infectious agents as causes of intraocular inflammatory disease (7, 8).

The route of *B. grahamii* infection in our patient is unclear. Various animals have been recognized as reservoirs for *Bartonella* species. *B. grahamii* was isolated from rodents in North America and Europe (3, 11). Domestic cats are a major reservoir for *B. henselae*, and a recently described subspecies, *B. clarridgeiae*, was also found in cats (13, 14). *B. vinsonii* has been cultured from the blood of a dog with endocarditis (4). Furthermore, studies suggested that not only fleas but also the human body louse, the sand fly, and ticks are possible vectors in the transmission of *Bartonella* species (16). Our patient described here owned a dog but had a negative history of cat ownership or cat scratches and had never been bitten or been in contact with small rodents. The existence of nonfeline infectious sources may explain the occurrence of ocular bartonellosis in the absence of previous contact with cats.

In previous studies, ocular bartonellosis was mainly associated with *B. henselae* infections; however, this association was predominantly based solely on serological grounds (9, 12, 18). The present case suggests that ocular bartonellosis might also be caused by other *Bartonella* species, and therefore, ocular bartonellosis may also be present in patients lacking the systemic symptoms of CSD. The presence of IgG against *B. henselae* in the serum of our patient, as determined by EIA, is probably due to cross-reactivity between *B. henselae* and *B. grahamii*. Cross-reactivity between different *Bartonella* species has been described earlier (28).

The diagnosis of human bartonellosis may be extremely troublesome, since the typical clinical features are not always present and the interpretation of the results of serological tests is difficult, as cross-reactivity between different *Bartonella* species has been observed (2, 28). Therefore, the diagnosis of bartonellosis should preferably rely on the detection of the infectious agent or the DNA of the infectious agent in the affected tissue. As patients with intraocular inflammation do not have tissues that are easily available for biopsy, diagnostic vitrectomy and retinal biopsy are recommended for patients with severe cases that threaten visual acuity (29). However, these surgical procedures are invasive and have considerable complication rates (27). Analysis of aqueous humor collected by anterior chamber tap, which was reported to be a safe diagnostic procedure for patients with uveitis, had diagnostic value even for patients with inflammatory lesions located in the posterior segment of the eye, such as the lesions associated with toxoplasmosis (7, 8, 26). In the previous studies, PCR analysis of intraocular fluids was specifically recommended for patients with early infections (and for immunosuppressed patients), since PCR positivity was mainly found for samples collected within 2 weeks after the onset of the disease (7, 8). The *Bartonella* PCR is usually performed with pus aspirates and lymph nodes from patients in the acute stages of the disease (1). A study of CSD encephalitis also showed that a PCR for detection of *B. henselae* in CSF was predominantly positive early in the course of the disease (23). In our patient, 1 year after the onset of the disease, *B. grahamii* DNA was present in the eye. The pathogenesis of intraocular inflammatory disease in patients with bartonellosis is not clear. The direct involvement of *B. henselae* in uveitis was supported by the detection of *B. henselae* DNA in a retinal lesion of an AIDS patient. In immunocompetent patients, ocular disease usually develops after systemic involvement has subsided, suggesting

that ocular involvement represents a late complication of the disease (9, 18). However, this assumption cannot be confirmed by previous studies, because serology was performed mainly by IFA and no specific IgM titers were determined for these patients (6, 9, 19, 30). The late manifestation of ocular involvement might be explained by the persistence of bacteria in the eye, which is shielded from the peripheral circulation by the blood-ocular barrier. This presumably occurred in our patient. An alternative hypothesis for the development of uveitis in a late stage of systemic bartonellosis may be that the bacteria have an indirect role, in that they induce a late (auto)immune reaction. The presence of *B. grahamii* DNA in our patient indicates that the direct microbial involvement may occur in HIV-negative patients. The late onset of intraocular inflammation in patients with systemic infections is a well-known phenomenon in uveitic disease; it is characteristic for herpetic retinopathies and toxoplasmic retinitis (25). In patients with bacterial infections such as syphilis, tuberculosis, leptospirosis, and borreliosis, the late involvement also occurs and is usually associated with the presence of bacteria or bacterial DNA in the eye (10, 15, 17, 22).

We demonstrated *B. grahamii* DNA in the intraocular fluids of a patient with neuroretinitis who was subsequently treated and reacted well to antibiotic therapy and who would otherwise be treated with immunosuppressive medication. Therefore, we would include bartonellosis in the differential diagnosis of patients with intraocular inflammatory disease, especially in those patients with neuroretinitis. Depending on the clinical manifestations and outcomes of laboratory examinations, we recommend that intraocular fluids be tested for infectious agents before initiating immunosuppressive treatment as a result of the symptomatology, especially in those patients with an unexplained cause of intraocular inflammation and clinical features suggesting an infectious disease. Future studies are needed to establish the involvement of different *Bartonella* species in human ocular disease.

REFERENCES

- Bergmans, A. M. C., J. W. Groothedde, J. F. P. Schellekens, J. D. A. van Embden, et al. 1995. Etiology of cat scratch disease: comparison of polymerase chain reaction detection of *Bartonella* (formerly *Rochalimaea*) and *Afpia felis* DNA with serology and skin tests. *J. Infect. Dis.* 171:916-923.
- Bergmans, A. M. C., M. F. Peeters, J. F. P. Schellekens, M. C. Vos, L. J. M. Sabbe, J. M. Ossewaarde, H. Verbakel, H. J. Hooft, and L. M. Schouls. 1997. Pitfalls and fallacies of cat scratch disease serology: evaluation of *Bartonella henselae*-based indirect fluorescence assay and enzyme-linked immunoassay. *J. Clin. Microbiol.* 35:1931-1937.
- Birtles, R. J., T. G. Harrison, and D. H. Molyneux. 1994. *Grahamella* in small woodland mammals in the U.K.: isolation prevalence and host specificity. *Ann. Trop. Med. Parasitol.* 88:317-327.
- Breitschwerdt, E. B., D. L. Kordick, D. E. Malakey, B. Keene, T. L. Hadfield, and K. Wilson. 1995. Endocarditis in a dog due to infection with a novel *Bartonella* subspecies. *J. Clin. Microbiol.* 33:154-160.
- Carithers, H. A. 1978. Oculoglandular disease of Parinaud. *Am. J. Dis. Child.* 132:1195-1200.
- Cohen, S. M., J. L. Davis, and D. M. Gass. 1995. Branch retinal arterial occlusion in multifocal retinitis with optic nerve edema. *Arch. Ophthalmol.* 113:1271-1276.
- de Boer, J. H., L. Luyendijk, A. Rothova, and A. Kijlstra. 1995. Analysis of ocular fluids for local antibody production in uveitis. *Br. J. Ophthalmol.* 79:610-616.
- de Boer, J. H., C. Verhagen, M. Bruinenberg, A. Rothova, et al. 1996. Serologic and polymerase chain reaction analysis of intraocular fluids in the diagnosis of infectious uveitis. *Am. J. Ophthalmol.* 121:650-658.
- Golnik, K. C., M. E. Marotto, M. M. Fanous, et al. 1994. Ophthalmic manifestations of *Rochalimaea* species. *Am. J. Ophthalmol.* 118:145-151.
- Hira, S. K., S. M. Shukla, and M. R. Mubanga. 1985. Uveitis in secondary syphilis: a report of treponemes in aqueous humor. *Eur. J. Sex. Transm. Dis.* 8:107-109.
- Hofmeister, E. K., C. P. Kolbert, A. S. Abdulkarim, J. M. H. Magera, et al. 1998. Cosegregation of a novel *Bartonella* species with *Borrelia burgdorferi* and *Babesia microti* in *Peromyscus leucopus*. *J. Infect. Dis.* 177:409-416.
- Kerkhoff, F. T., J. M. Ossewaarde, W. S. de Loos, and A. Rothova. Presumed

- ocular bartonellosis. *Br. J. Ophthalmol.*, in press.
13. **Koehler, J. E., C. A. Glaser, and J. W. Tappero.** 1994. *Rochalimaea henselae* infection. A new zoonosis with the domestic cat as reservoir. *JAMA* **7**:531–535.
 14. **Kordick, D. L., E. J. Hilyard, T. L. Hadfield, K. H. Wilson, A. G. Steigerwaldt, D. J. Brenner, and E. B. Breitschwerdt.** 1997. *Bartonella clarridgeiae*, a newly recognized zoonotic pathogen causing inoculation papules, fever, and lymphadenopathy (cat scratch disease). *J. Clin. Microbiol.* **35**:1813–1818.
 15. **Kox, L. F. F., H. M. Jansen, S. Kuijper, and A. H. J. Kolk.** 1997. Multiplex PCR assay for immediate identification of the infecting species in patients with mycobacterial disease. *J. Clin. Microbiol.* **35**:1492–1498.
 16. **Maurin, M., R. J. Birtles, and D. Raoult.** 1997. Current knowledge of *Bartonella* species. *Eur. J. Clin. Microbiol. Infect. Dis.* **16**:487–506.
 17. **Merien, F., P. Perolar, E. Mancel, D. Persan, and G. Baraton.** 1993. Detection of *Leptospira* DNA by polymerase chain reaction in aqueous humour of a patient with unilateral uveitis. *J. Infect. Dis.* **168**:1335–1336.
 18. **Ormerod, D., K. A. Skolnick, M. M. Menesky, P. R. Pavan, and D. M. Pon.** 1998. Retinal and choroidal manifestations of cat-scratch disease. *Ophthalmology* **105**:1024–1031.
 19. **Regnery, R. L., J. G. Olson, B. A. Perkins, and W. Bibb.** 1992. Serological response to “*Rochalimaea henselae*” antigen in suspected cat-scratch disease. *Lancet* **339**:1443–1445.
 20. **Relman, D. A., J. S. Loutit, T. M. Schmidt, S. Falkow, and L. S. Tompkins.** 1990. The agent of bacillary angiomatosis. An approach to the identification of uncultured pathogens. *N. Engl. J. Med.* **323**:1573–1580.
 21. **Sabates, R., R. C. Pruett, and R. J. Brockhurst.** 1981. Fulminant ocular toxoplasmosis. *Am. J. Ophthalmol.* **92**:497–503.
 22. **Schubert, H. D., E. Greenebaum, and H. C. Neu.** 1994. Cytologically proven seronegative Lyme choroiditis and vitritis. *Retina* **14**:39–42.
 23. **Schwartzman, W. A., M. Patnaik, N. E. Barka, and J. B. Peter.** 1994. *Rochalimaea* antibodies in HIV-associated neurologic disease. *Neurology* **44**:1312–1316.
 24. **Soheilian, M., N. Markomichelakis, and C. S. Foster.** 1996. Intermediate uveitis and retinal vasculitis as manifestations of cat scratch disease. *Am. J. Ophthalmol.* **122**:582–583.
 25. **Suttrop, M. S. A., and A. Rothova.** 1996. The possible impact of uveitis in blindness, a literature survey. *Br. J. Ophthalmol.* **80**:844–848.
 26. **van der Lelij, A., and A. Rothova.** 1997. Diagnostic anterior chamber paracentesis in uveitis: a safe procedure? *Br. J. Ophthalmol.* **81**:976–979.
 27. **Verbraeken, H.** 1996. Diagnostic vitrectomy and chronic uveitis. *Graefes Arch. Clin. Exp. Ophthalmol.* **234**:S2–S7.
 28. **Waldvogel, K., R. L. Regnery, R. Anderson, R. Caduff, J. Caduff, and D. Nadal.** 1994. Disseminated cat-scratch disease: detection of *Rochalimaea henselae* in affected tissue. *Eur. J. Pediatr.* **153**:23–27.
 29. **Warren, K., E. Goldstein, V. S. Hung, J. E. Koehler, and W. Richardson.** 1998. Use of retinal biopsy to diagnose *B. henselae* retinitis in an HIV-infected patient. *Arch. Ophthalmol.* **116**:937–940.
 30. **Zacchei, A. C., N. J. Newman, and P. Sternberg.** 1995. Serous retinal detachment of the macula associated with cat scratch disease. *Am. J. Ophthalmol.* **120**:769–770.